

How to Use an Epidural in a Field Situation for Analgesia or Local Anesthesia

Jenifer R. Gold, DVM, Diplomate ACVIM

Author's address: Department of Large Animal Clinical Sciences, Texas A&M University, 4475 TAMU, College Station, TX 77845; e-mail: jgold@cvm.tamu.edu. © 2008 AAEP.

1. Introduction

The use of the epidural space for administration of drugs for analgesia and anesthetic has become fairly common in the horse. An epidural injection can be administered easily in the field to assist with a variety of issues including but not limited to dystocia, rectal prolapse, uterine prolapse, surgery of the rectum, vagina, perineum and/or bladder/urethra as well as pain control. The epidural space is accessible at the lumbosacral joint (cranial epidural) or caudal to the sacrum (caudal epidural). The caudal epidural (sacrococcygeal or C1–C2 space) is the preferred space to use, because it is easier and safer to perform in the field.

The caudal epidural space has no risk for dural or CSF puncture and less risk for motor blockade and ataxia. However, one must realize that when a large volume of drug is injected, the injectate can move cranially and cause other more proximal regions of anesthesia/analgesia; this can result in ataxia.¹ The cranial epidural space (lumbosacral space) is less commonly used. Accessing the cranial epidural space can be more difficult, particularly in well-muscled or obese horses. The procedure requires longer needles, and the landmarks are less obvious. Dural puncture and potential for acquiring cerebral spinal fluid is greater in the more cranial space. An in-

creased risk of motor blockage and ataxia is also present.

The purposes of this paper are to describe how to perform a caudal epidural injection in the field quickly and safely and to provide examples of medications that can be used.

2. Materials and Methods

In review, the spinal cord extends distally to the caudal side of the second sacral vertebrae. This is just caudal to the sacroiliac joint. The landmark for the epidural injection is located by finding the first movable space at the tail head. Either the first or second space can be used. The tail is moved up and down to allow for palpation of the intervertebral spaces. It is important to become comfortable with the anatomy of this area (Fig. 1). The caudal epidural space is ~1–3 in (2.5–7.5 cm) cranial to the start of the tail hairs.² The depth of the space varies anywhere from 1 to 4 inch depending on the individual animal. Before injection, the hair is clipped in a square that is ~6 × 6 in (15 × 15 cm), and the area is aseptically prepared (Fig. 2).³ Superficial local infiltration of a local anesthetic (1–2 ml of lidocaine or carbocaine with a 22-g needle) at the site of injection helps with the insertion of the needle (Fig. 3). This procedure can be performed in

NOTES

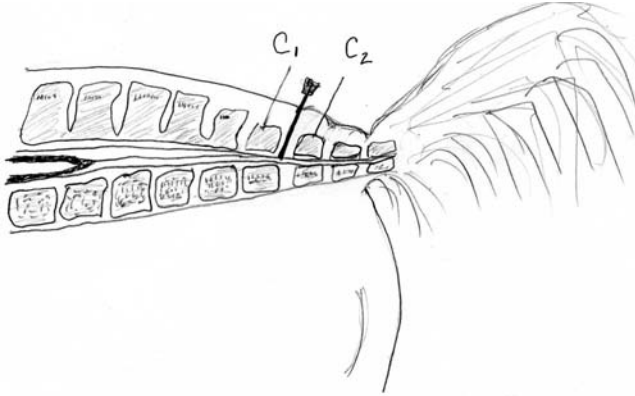


Fig. 1. Schematic for placement of needle for a caudal epidural injection.

a sedate or awake horse, depending on the situation and surroundings. Heavily sedated horses tend to not stand squarely, making it more difficult to stay on midline when inserting the needle.

After the horse is clipped, aseptically prepared, and blocked, the injection can be performed. The needle or spinal-needle sizes that can be used are

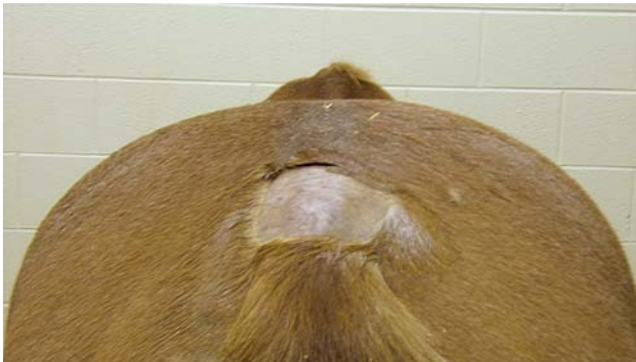

Fig. 2. Area where hair is clipped for caudal epidural catheter placement. The hair is clipped in an $\sim 6 \times 6$ -in (15×15 -cm) square and aseptically prepared.

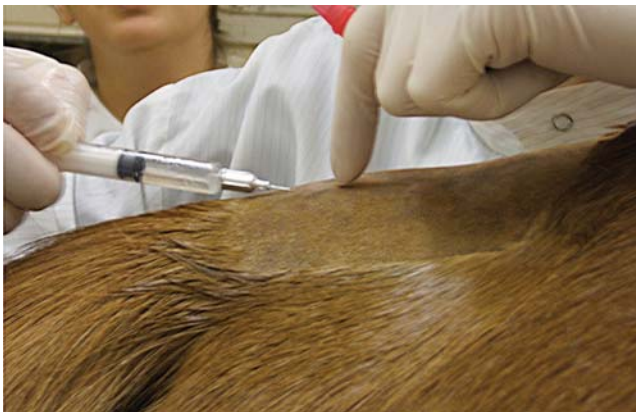

Fig. 3. Infiltration of lidocaine into skin and subcutaneous tissue before caudal epidural.

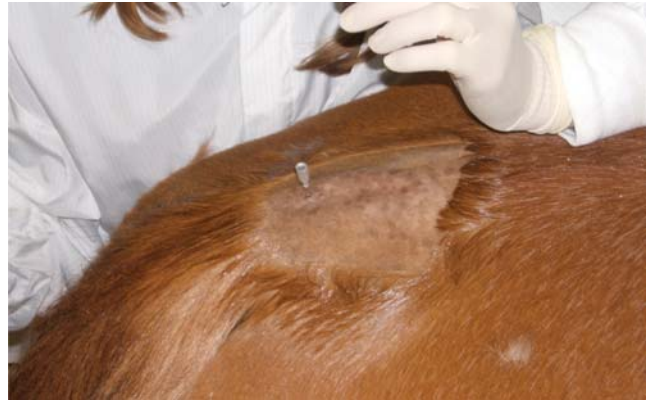

Fig. 4. Placement of 1.5-in, 18-g needle for caudal epidural catheter. Note the hanging drop.

18–22 g and 1.5–3.5 in, depending on the size and body condition of the horse (Figs. 4 and 5). If the horse is going to need multiple injections in the epidural space, an epidural catheter should be considered.

Before injection, the syringe should be ready with aseptically drawn medication, and sterile gloves should be used. The intervertebral space should be palpated again before placement of the needle. The owner or a technician should move the tail up and down to relocate the injection site. The horse should be standing squarely, and the needle should be placed midline. The needle is placed almost perpendicular to the plane of the skin with the bevel of the needle facing cranially. The needle is pushed downward until the inarcuate ligament (ligamentum flavum) is perforated.² Sometimes a popping sensation is noted when the ligament has been punctured.² If the needle is advanced too far and the floor of the vertebral body is reached, the needle

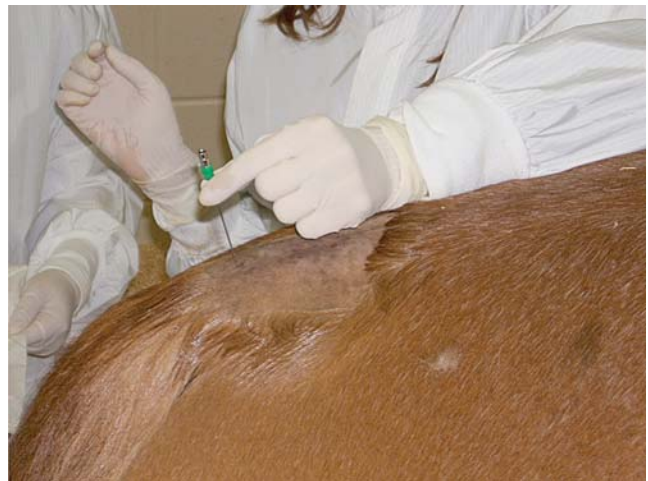

Fig. 5. Proper insertion of spinal needle for a caudal epidural injection.

should be withdrawn ~0.5 cm to preclude injection into the intervertebral disc.²

The correct position of the needle should be verified by methods described below. One should also aspirate to make sure the venous sinus is not inadvertently perforated.

Several methods exist for verification of needle placement into the epidural space. One method is the hanging drop technique where, after the needle is through the skin and subcutaneous tissue, a drop of saline or a drug can be placed in the hub of the needle. When the needle enters the epidural space, negative pressure will cause the drop to be aspirated. The second method is to try to inject air into the needle that is in the epidural space. If the needle is in the space, no resistance should occur, and the air will be pushed in easily. After the needle is in the space, the drug can be administered. If none of the methods above were used and resistance is noted while injecting, the needle is not in the correct position. A new needle should be obtained and used.

The volume of injection can be increased with 0.9% preservative-free saline.⁴ If the volume to be injected is <10 ml, it can be injected in <1 min. If the volume to be injected is >10 ml, the injection should be done slowly because of the compression of the nerve endings in the epidural space. If the

injection is performed too rapidly, the horse can become recumbent.⁴ Contraindications for use of the epidural injection are infection or inflammation near the site of the injection. Other contraindications for epidural injections are spinal-cord disease, musculoskeletal weakness or debilitation, all of which could result in severe ataxia or recumbency.^{1,2}

Medications

The beauty of using an epidural in the field situation is that many of the drugs used are commonly found within an ambulatory veterinarian's pharmacy.

Local Anesthetics

The main indication for local anesthetics is for perineal anesthesia. Common local anesthetics induce a dose-related blockade of sensory and motor pathways. Higher doses or volumes of local anesthetics can travel rostrally, which can lead to severe ataxia, paresis, and hypotension.²

Lidocaine, a sodium-channel blocker, is the most commonly used local anesthetic for epidural injection.⁴⁻⁷ It is commonly packaged in a 2% concentration. Caudal epidural local anesthesia in horses does not progress cranially enough to produce sympathetic blockade cranial to the hindlimb. Onset of anesthesia is noted by relaxation of the tail and

Table 1. Drugs Used for Epidural Injection in the Horse

Drug	Dose	Onset of action	Duration of action	Administration	Indication
Lidocaine 2%	0.2–0.25 mg/kg	6–10 min	45–60 min	8 ml can dilute to 10 ml*	Anesthesia
Mepivacaine	0.2–0.25 mg/kg	6–10 min	45–90 min	8 ml can dilute*	Anesthesia
Ropivacaine	0.8 mg/kg	10 min	3 hr	8 ml can dilute*	Anesthesia
Morphine preservative free	0.1–0.2 mg/kg Less conc.	1–5 hr	6–16 hr	Can dilute to 20–30* ml slow	Analgesia
Morphine	0.1–0.2 mg/kg	1–5 hr	6–16 hr	More concentrated Dilute!*	Analgesia
Methadone 1% preservative free	0.1 mg/kg	15 min	5 hr	Dilute	Analgesia
Tramadol	1 mg/kg	<30 min	5 hr	Dilute to 20–30 ml*	Analgesia
Xylazine	0.17–0.22 mg/kg	15–30 min	3.5 hr	10 ml* for perineal 20–30 ml for rostral	Analgesia
Detomidine	0.01–0.06 mg/kg	10–25 min	2 hr	Dilute max 10 ml*	Analgesia
Ketamine	0.5–2 mg/kg	10 min	30–75 min	Can dilute 10–30 ml*	Analgesia
Opioids and α_2 agonist combo	0.1–0.2 mg/kg Morphine 0.17 mg/kg xylazine or 0.01 mg/kg detomidine	Longer onset	Longer duration	MAX 10 ml*	Analgesia
α_2 agonist and local anesthetic	0.17 mg/kg xylazine or 0.01–0.06 mg/kg detomidine and 0.06 mg/kg lidocaine or mepivacaine. Decrease local anesthetic by 30%	15 min	Longer duration	Max 10 ml*	Anesthesia

*Dilution is with preservative free 0.9% saline

**These doses are recommended for the caudal epidural site. Doses differ if using the cranial epidural site.

anus. Mepivacaine 2%, another sodium-channel blocker, will increase the duration of action.⁸ It is recommended to use <10 ml of local anesthetic in the caudal epidural space in adult horses to prevent paralysis of the lumbosacral nerves to the hind limbs.^{1,8} Bupivacaine is a local anesthetic of high potency and longer duration because of its high lipidsolubility.^{9,10} It can be used when anesthesia of greater duration is needed. Several studies have shown it to be safe and efficacious in the horse.^{9,10}

Xylazine or Detomidine

Administration of alpha-2 agonists in the epidural space provides analgesia for a longer duration than equivalent systemic doses. High doses of these drugs can cause motor and sensory blockade, which can cause ataxia and paresis. Systemic effects, such as sedation, hyper/hypotension, and bradycardia, can be seen when using these drugs in the epidural space. Xylazine¹¹⁻¹³ or detomidine^{14,15} can also be used in combination with a sodium-channel blocker (local anesthetic).^{1-3,6} Detomidine can be used in combination with morphine to increase duration of pain management.¹⁶⁻¹⁸

Opioids

The use of opioids for the treatment of post-operative pain or chronic pain has become very popular in veterinary medicine.^{1,18,19} The major benefits of opiates over other drugs are that they provide sensory blockade without affecting motor neurons, which causes much less ataxia.^{1,2,18,19} The side effects are few if given in appropriate dosages, and the duration of action can be upwards of 18 h. Morphine can decrease the need for non-steroidal anti-inflammatory drugs (NSAIDs) and thus, reduce the possibility of NSAID toxicity. Morphine and methadone are the most effective opioids for epidural injection, because others have been proven to be less effective and are not recommended.^{1,2} The effects of morphine or methadone are systemic, whereas the effects of alpha-2 drugs are both systemic and local in nature. Preservative-free morphine is recommended^{1,3,17,18} but can be very expensive; also, it is less concentrated (1 mg/ml) than preservative-containing morphine (10 mg/ml).¹ If using preservative-containing morphine, use a 0.22- μ m filter during injection as well as preservative-free 0.9% saline.¹ Using preservative-free 0.9% saline decreases the changes of neurotoxicity from preservatives in the morphine.¹

Tramadol

At a dose of 1 mg/kg, tramadol has been shown to have good analgesia in the horse.^{1,20} The duration is not quite as long lasting as morphine, and it is more expensive. Please note that IV tramadol is not available in the United States.

Ketamine

Epidural ketamine blocks the N-methyl D-aspartate (NMDA) receptors in the spinal cord.^{1,21} Activation

of NMDA receptors causes the spinal-cord neuron to become more responsive to all of its inputs, which results in central sensitization. Thus, blocking the receptors helps to alleviate central sensitization. Ketamine has a fast onset of analgesic action (~10 min) and a short duration of action (30–75 min) that is dose dependant.^{1,21} Ketamine can cause sedation or ataxia at higher doses, but overall, it seems to be a safe and good epidural analgesic.^{1,21}

3. Results and Discussion

Epidural injections of local anesthetics in the horse were first described in Europe over 75 years ago.² However, the procedure still has not gained as wide acceptance in horses as it has in small animals. Likely, this has to do with the epidural being slightly more difficult in the equine patient than bovine or small ruminant patients. However, with the advances in epidural techniques and especially with appropriate drugs, this technique should and can be used more often. In a field situation, an epidural can be performed safely and assist the ambulatory veterinarian in a wide variety of situations. An epidural can be used during a dystocia to help correct the position of the foal with the mare standing. It can be used to help decrease tenesmus and replace a prolapsed rectum or uterus, which allows for both analgesia and pain management. The technique can also be used for standing surgeries like perineal urethroscopy, rectovaginal tears, vaginal lacerations, and more. Epidural injections can also help decrease the pain in many situations, particularly if given before a procedure (i.e., ovariectomy or cystotomy). Overall, after practitioners become familiar with the anatomy and the ease of the epidural technique, it can be used in a multitude of applications.

References

- Doherty T, Valverde A. Epidural analgesia and anesthesia. In: Doherty T, Valverde A, eds. *Manual of equine anesthesia and analgesia*. Ames, IA: Blackwell Publishing, 2006;275–281.
- Robinson EP, Natalini CC. Epidural anesthesia and analgesia in horses. In: Turner AS, Khurshheed MR, Hendrickson DA, eds. *Pain management and anesthesia*. *Vet Clin North Am Equine Pract*, Philadelphia, PA: W.B. Saunders Co., 2002;61–71.
- Ball MA, Cable CS, Kirker EJ. How to place an epidural catheter and indications for its use, in *Proceedings*. 44th Annual American Association of Equine Practitioners Convention 1998;182–185.
- Fikes LW, Lin HC, Thurman JC. A preliminary comparison of lidocaine and xylazine as epidural analgesics in ponies. *Vet Surg* 1989;18:85–86.
- Green EM, Cooper RC. Continuous caudal epidural anesthesia in the horse. *J Am Vet Med Assoc* 1984;184:971–974.
- Grubb TL, Riebold TW, Huber MJ. Comparison of lidocaine, xylazine, and xylazine/lidocaine for caudal epidural analgesia in horses. *J Am Vet Med Assoc* 1992;202:1187–1190.
- Schelling CG, Klein LV. Comparison of carbonated lidocaine and lidocaine hydrochloride for caudal epidural anesthesia in horses. *Am J Vet Res* 1985;46:1375–1377.
- Skarda RT, Muir WW, Ibrahim AI. Plasma mepivacaine concentrations after caudal epidural and subarachnoid injection in the horse: comparative study. *Am J Vet Res* 1984; 45:1967–1971.

9. DeRossi R, Miguel GLS, Frazilio FO, et al. L-Bupivacaine 0.5% vs racemic 0.5% bupivacaine for caudal epidural analgesia in horses. *J Vet Pharmacol Therp* 2005;28:293–297.
10. DeRossi R, Sampaio BFB, Varela JV, et al. Perineal analgesia and hemodynamic effects of the epidural administration of meperidine or hyperbaric bupivacaine in conscious horses. *Can Vet J* 2004;45:42–47.
11. LeBlanc PH, Caron JP, Patterson JS, et al. Epidural injection of xylazine for perineal analgesia in horses. *J Am Vet Med Assoc* 1988;193:1405–1408.
12. LeBlanc PH, Caron JP. Clinical use of epidural xylazine in the horse. *Equine Vet J* 1990;22:180–181.
13. Doherty TJ, Geiser DR, Rohrbach BW. The effect of epidural xylazine on halothane minimum alveolar concentration in ponies. *J Vet Pharmacol Ther* 1997;20:246–248.
14. Skarda RT, Muir WW. Caudal analgesia induced by epidural or subarachnoid administration of detomidine hydrochloride solution in mares. *Am J Vet Res* 1994;55:670–680.
15. Skarda RT, Muir WW. Comparison of antinociceptive, cardiovascular, and respiratory effects, head ptosis, and position of pelvic limbs in mares after caudal epidural administration of xylazine and detomidine.
16. Sysel AM, Pleasant RS, Jacobsen JD, et al. Efficacy of an epidural combination of morphine and detomidine in alleviating experimentally induced hindlimb lameness in horses. *Vet Surg* 1996;25:511–518.
17. Sysel AM, Pleasant RS, Jacobsen JD, et al. Systemic and local effects associated with long term epidural catheterization and morphine-detomidine administration in horses. *Vet Surg* 1997;26:141–149.
18. Goodrich LR, Nixon AJ. How to alleviate acute and chronic hindlimb pain in the horse, *Proceedings*. 49th Annual American Association of Equine Practitioners Convention 2003;262–267.
19. Natalini CC, Driessen B. Epidural and spinal anesthesia and analgesia in equine. In: *Clinical techniques in equine practice*. Philadelphia, PA: Elsevier, 2007;145–153.
20. Levionnois OL, Spadavecchia C, Bergadano A, et al. Use of opioids for horse analgesia with particular interest on epidural administration. *Pferdeheilkunde* 2005;21:311–316.
21. Gomez de Serura, De Rossi R, Santos M, et al. Epidural injection of ketamine for perineal analgesia in the horse. *Vet Surg* 1998;27:384–391.